

Imaging of breast hamartomas

Radia Benyahia¹, Fadwa. Hocine¹, Ouarda. Alliche¹, Imene EL Hafaia², Salah Eddine. Bendib¹

¹Medical Imaging Department, Centre Pierre et Marie Curie, University of Algiers 1, Algeria.

²Medical Anatomopathology Department, Centre Pierre et Marie Curie. Algiers 1 University, Algeria.

*Corresponding author

rad_rx@yahoo.fr

r.benyahia.univ.alger@gmail.com

Received: 02 Nov 2023; Received in revised form: 07 Dec 2023; Accepted: 14 Dec 2023; Available online: 21 Dec 2023

©2023 The Author(s). Published by AI Publications. This is an open access article under the CC BY license

(<https://creativecommons.org/licenses/by/4.0/>)

Abstract— Breast hamartoma is a rare, well-circumscribed, benign lesion made up of a variable quantity of glandular, adipose and fibrous tissue. This is a lesion that can affect women at any age from puberty. With the increasingly frequent use of imaging methods such as mammography and ultrasound as well as breast biopsy, cases of hamartoma diagnosed are increasing. The diagnosis of these lesions is made by mammography. The histological and radiological aspects are variable and depend on its adipose tissue content. The identification of these lesions is important in order to avoid surgical excisions. We report radio-clinical and pathological records of breast hamartoma.



Keywords – Hamartoma, Breast, Mammography

I. INTRODUCTION

Hamartomas are defined as rare benign tumors. Represents approximately 0.7% of all benign breast masses. These are lesions made of variable proportions of normal histological constituents of the parenchyma of the organ in which they develop. They can occur in several organs such as the lung, skin, breast. This study aims to report and present our experience with breast hamartomas as well as a review of the literature.

II. MATERIAL

This is a retrospective study spread over 5 years analyzing the radiological aspects of the three patients reported in the radiology and medical imaging department of the Pierre and Marie Curie Center in Algiers.

Result

The average age of our patients is 42 years old, the reason for consultation was a breast nodule discovered during self-palpation for 2 patients and the third an incidental discovery.

The clinical examination revealed a well-circumscribed mass, the size of which varied from 3 to 5 cm.

A mammogram is performed on all our patients showing an oval mass, with circumscribed contours, well defined, encapsulated, homogeneous of mixed density without microcalcifications. For the 1st case the fat density was predominant (figure 1a), for the 2nd case the density was of mixed type (figure 2a) and the 3rd case the density was of the glandular type (figure 3a).

On ultrasound, the echostructure remains similar to the surrounding breast tissue creating a “breast within the breast” appearance and suggesting a hamartoma (figure 1a, 2b, 3c).

An MRI is performed on a patient given the diagnostic difficulty due to a large mass of indeterminate appearance which revealed an encapsulated mass well limited in T1 hyposignal, heterogeneous by the presence of a fibrocystic dystrophy enhancing in a manner after injection of contrast product with a non-enhanced peripheral border suggestive of a hamartoma (figure 4).

Histological proof is carried out in all our patients confirming the diagnosis of hamartoma.

Long-term follow-up of our patients is based on simple clinical and ultrasound monitoring.

III. DISCUSSION

Breast hamartoma is a rare, benign tumor whose appearance owes it the name "breast within the breast" and as a result it will contain all the normal and pathological aspects of the breast.

Hamartoma was initially described by Arrigoni et al in 1971, as a histological structure comprising glandular structures organized in lobules, with fibrous stroma and fat reflecting the expression of "breast within the breast"

It is a malformation due to a developmental abnormality before birth. Histologically, the tumor presents normal breast tissue but arranged in an anarchic manner, which removes any functional role (1). Its incidence estimated at 0.1 to 0.7% of all benign breast tumors (2).

It is often mute and usually discovered incidentally. It can be diagnosed at any age from adolescence. The radiological and histological aspects depend on its content.

On clinical examination, hamartoma is most often asymptomatic, may be undetectable or appear as a mass [3], mobile and soft in consistency. This lesion is more or less painful, not painful. It is most often discovered during a breast cancer screening exam.

The diagnosis is made with standard imaging by mammography and breast ultrasound.

In mammography, the diagnosis is almost pathognomonic, highlighting a breast mass, round, oval in shape with circumscribed contours surrounded by a halo, fine radiolucent border, clear which corresponds to the pseudo capsule, of variable density, within which are juxtaposed greasy lightness and more or less dense opacities creating the typical "salami slice" appearance. An appearance of "breast within the breast" and the appearance of a double radiolucent component, fatty and dense by the presence of fibro-glandular tissue are also described according to the constitutions of the breast tissue (fat, gland, fibrous tissue), within the breast. of mass.

Microcalcifications or dystrophic calcifications are rarely seen within a hamartoma.

Ultrasound reveals a mass with circumscribed contours, oval in shape. Most often, there is no posterior reinforcement or cone of attenuation.

This mass is heterogeneous, associating iso-echoic areas with fat and hyperechoic areas like normal glandular tissue [4]. It can be the site of a galactocele or simple cyst as in our 3rd case.

Breast MRI is only indicated if there are signs of malignancy [5]. It shows a well-defined lesion with homogeneous T1 hyposignal, enhancing homogeneously after injection of contrast product with a peripheral border.

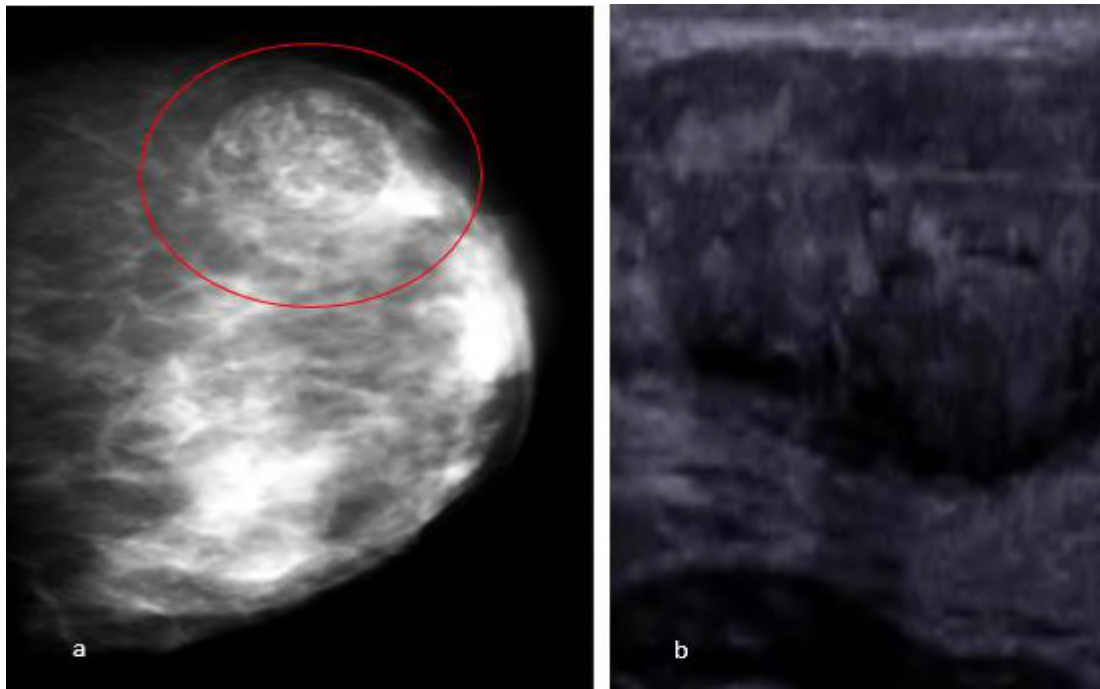


Fig.1.a: Mammography (craniocaudal incidence): typical mammographic appearance of a mammary hamartoma: oval mass with circumscribed contours and fatty density, classified as BIRADS2.

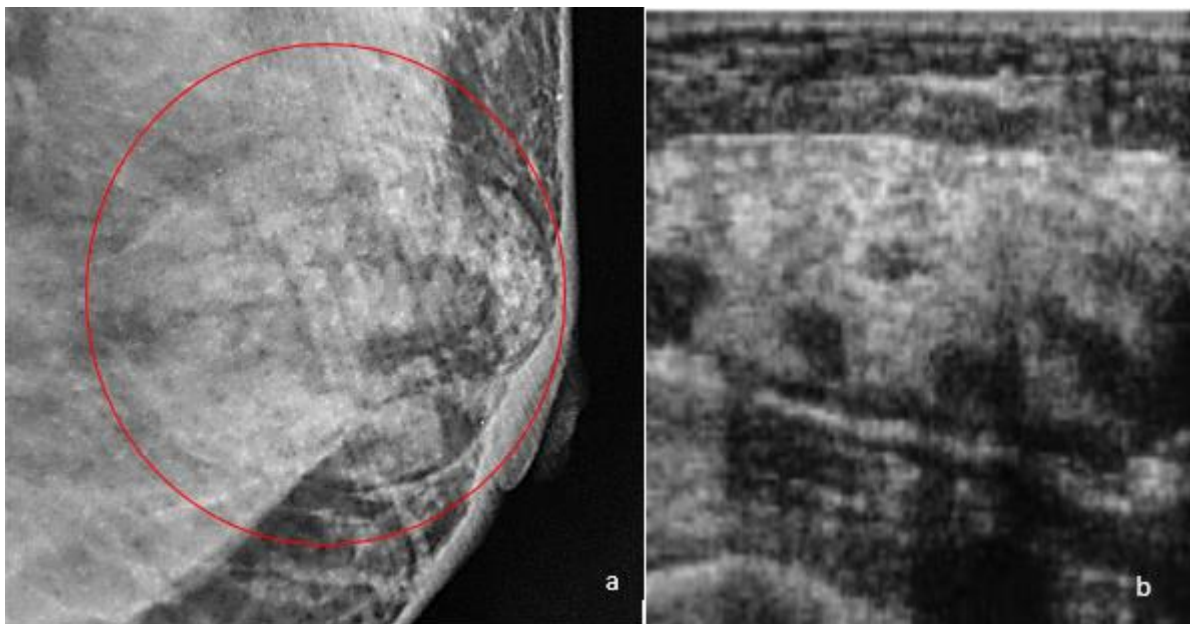


Fig.1b: Ultrasound mammography: oval, circumscribed mass with hypoechoic echostructure, classified BI-RADS 2.

Figure 2a: Mammography (craniocaudal incidence): typical mammographic appearance of a mammary hamartoma: rounded mass with circumscribed contours of predominantly conjunctival density surrounded by a peripheral halos, classified BI-RADS 2.

Figure 2b: Mammary ultrasound: sonographic appearance of a mammary mass: oval, circumscribed mass with echogenic echostructure, containing fatty pockets, classified BI-RADS 3.

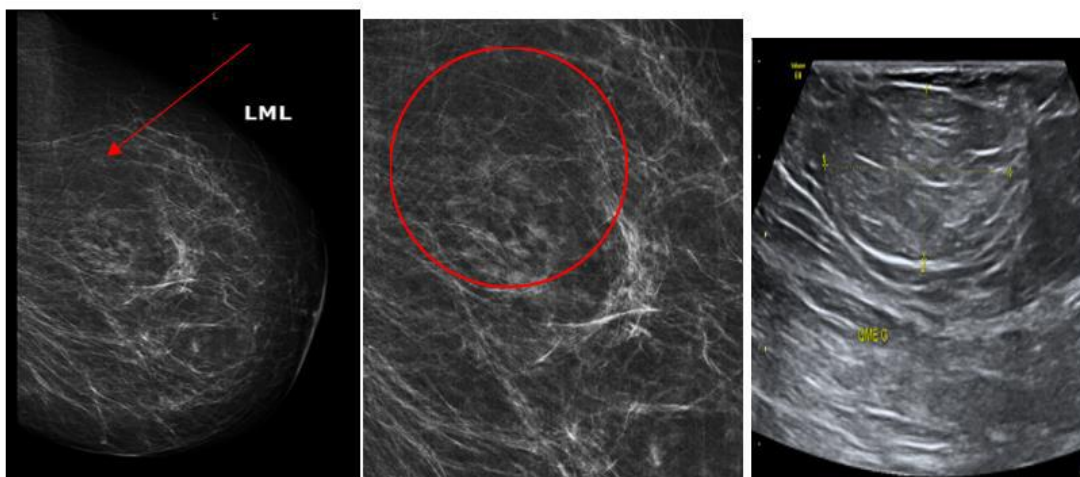


Fig.3 a: Mammogram (craniocaudal incidence): typical mammographic appearance of a mammary hamartoma: rounded, circumscribed mass of mixed glandular and fat density surrounded by a peripheral opaque halos, classified BI-RADS3.

Fig.3b: Mammary ultrasound: sonographic appearance of a mammary mass: oval mass with circumscribed contours of hypoechoic echostructure, containing glandular logettes, classified BI-RADS 3.

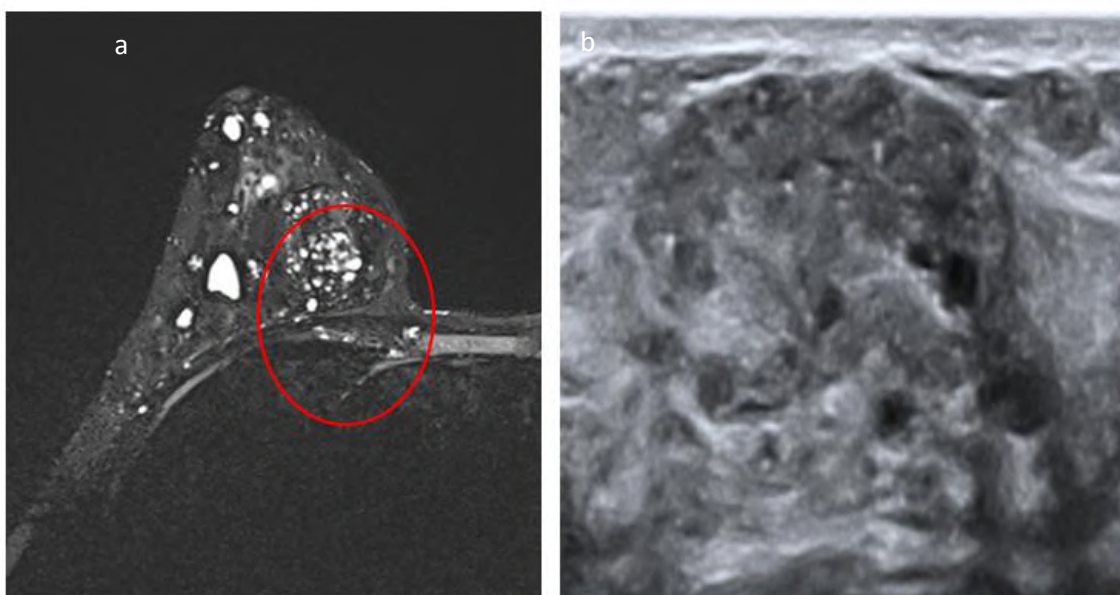


Fig.4: Breast MRI.

- a : T1 fat sat-weighted axial sequence: well-limited mass of the right breast in hyposignal, heterogeneous .containing microcysts

- b : Mammary ultrasound: ultrasonographic appearance of a breast mass: oval mass with circumscribed contours of heterogenic echostructure containing microcysts within, classified BI-RADS 3.

REFERENCES

- [1] Vergine M, Scipioni P, Santucci E, et al. Hamartome du sein chez une femme jeune. *Rapport de cas. Il Giornale di Chirurgia*. 2013 ; 34 (5-6):161-163
- [2] A. Presazzi ,G. Di Giulio ,et F. Calliada Hamartome mammaire : caractéristiques échographiques, élastosonographiques et mammographiques [Échographie J.](#) 2015 décembre ; 18(4): 373-377.
- [3] Tavassoli F.A., Devilee P. From tumors of the breast, fibroepithelial tumors. In the WHO Classification of tumours: pathology and genetics of tumours of the breast and female genital organs: IARC Press, 2002; 103.
- [4] G M K Tse, B K B Law, T K F Ma, A B W Chan, L-M Pang, W C W Chu, H S Cheung : Hamartoma of the breast: a clinicopathological review. *J Clin Pathol* 2002, 55:951-954.
- [5] BOUFETTAL H, MAHDAOUI S, NOUN M, HERMAS S, SAMOUH N. Hamartome mammaire. *Feuillets de radiologie* 2010; 50 : 189-191.